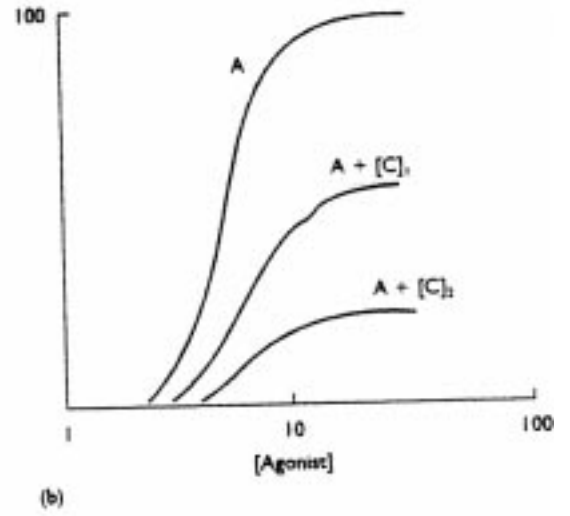
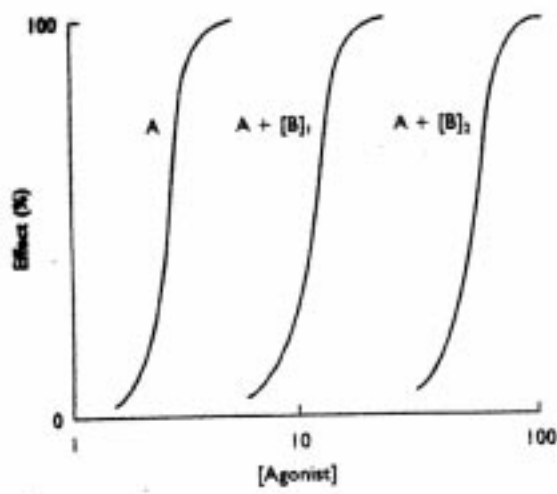


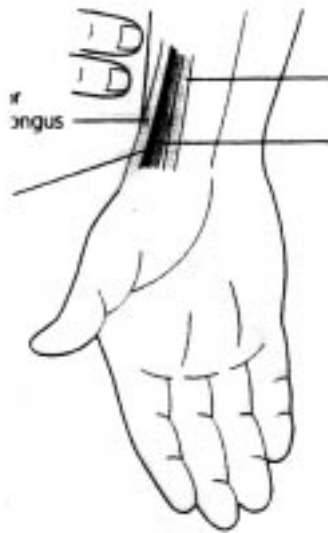
A
Simple Drawing

SIMPLE DRAWING



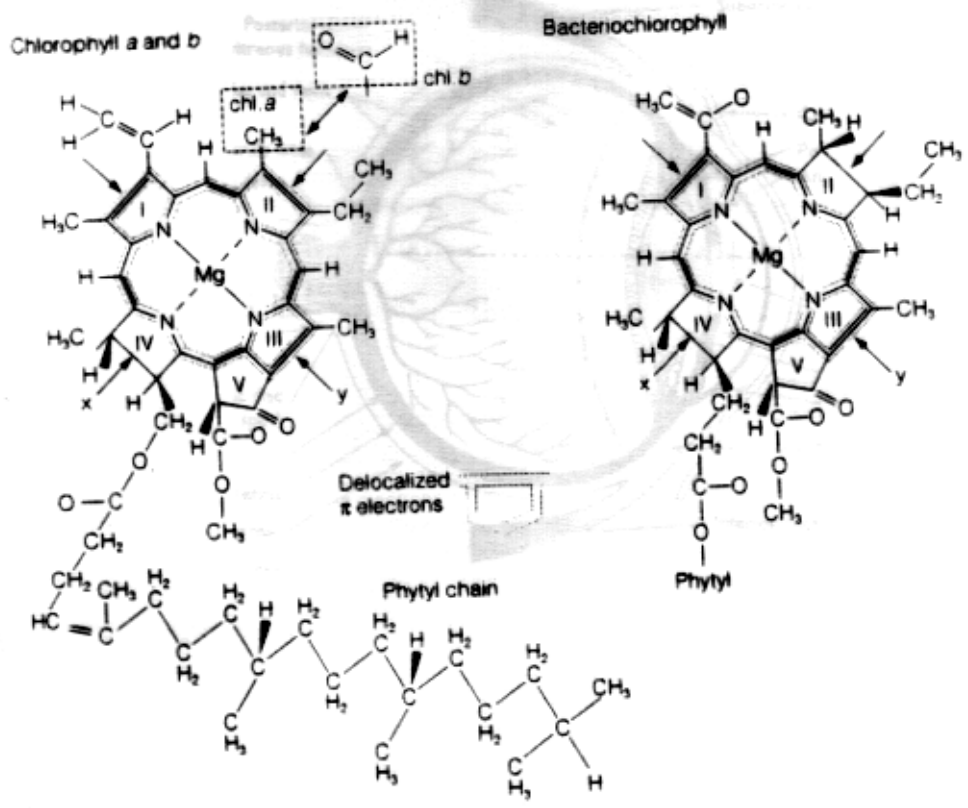
B
MEDIUM DRAWING

MEDIUM DRAWING



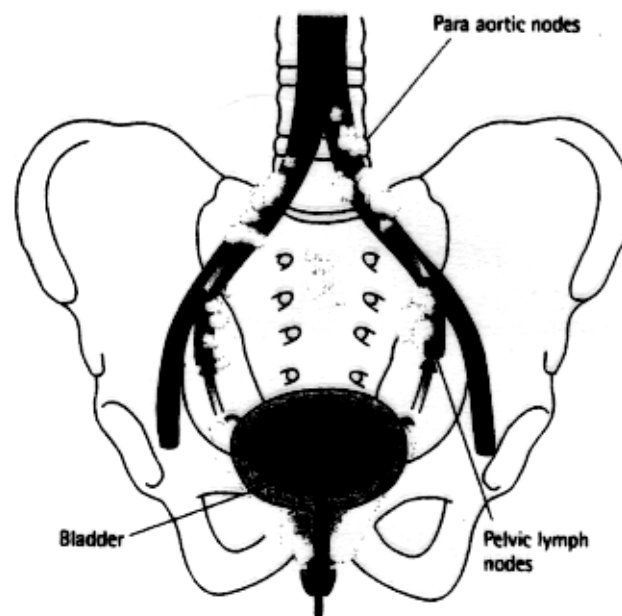
C
COMPLEX DRAWING

COMPLEX DRAWING



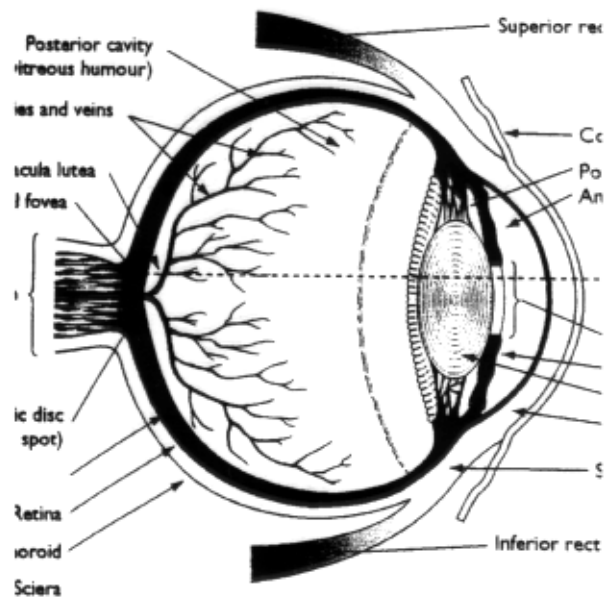
D
2-D LOW COMPLEX

2-D LOW COMPLEX



E
2-D MEDIUM COMPLEX

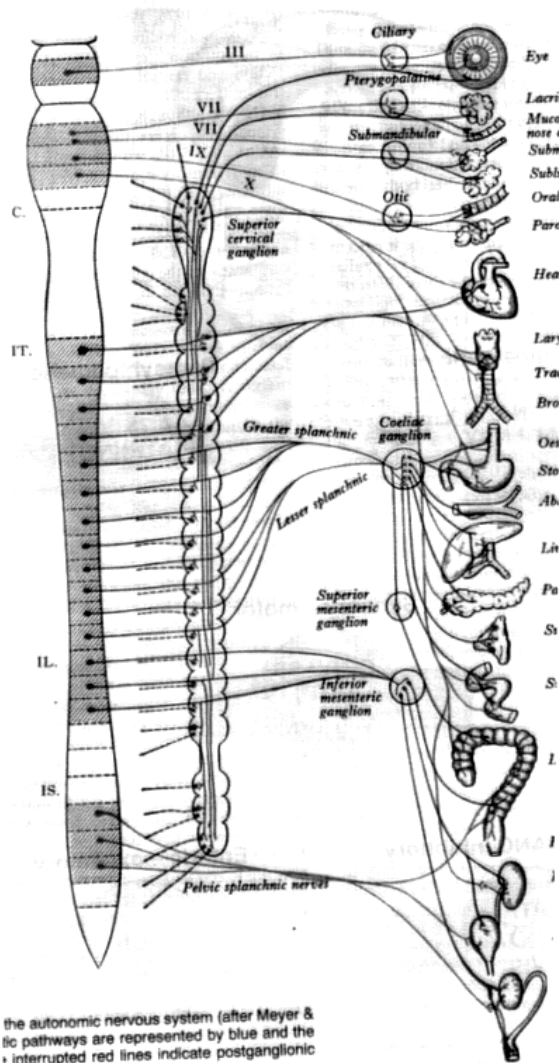
2-D MEDIUM COMPLEX



F

2-D HIGH COMPLEX

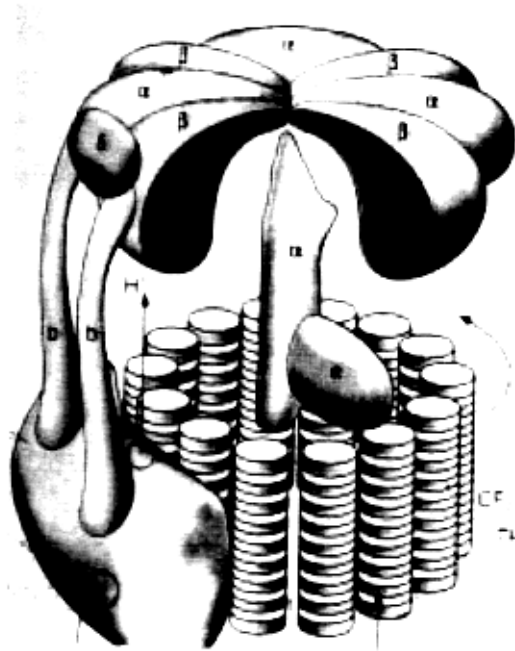
2-D HIGH COMPLEX



the autonomic nervous system (after Meyer & ...
tic pathways are represented by blue and the ...
interrupted red lines indicate postganglionic

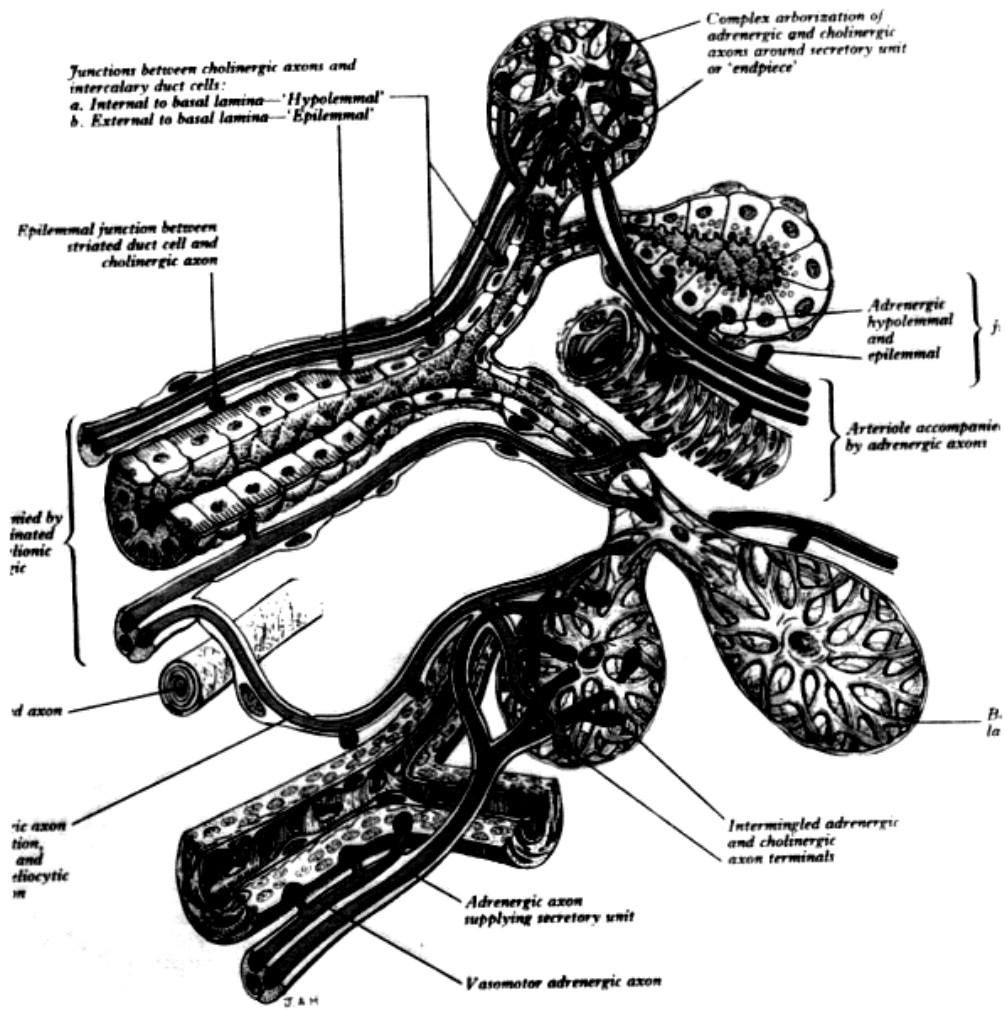
G
3-D LOW COMPLEX

3-D LOW COMPLEX



H
3-D MEDIUM COMPLEX

3-D MEDIUM COMPLEX



ervation of the ducts, secretory units and arterioles in a

I
3-D HIGH COMPLEX

